

Left hand acheiria in 3 newborns within a period of 3 months during the year 2011 in Fallujah general hospital

Samira Telfah Alaani^{1*}, Abdulkadir Abdulkareem Miri'e²

¹Pediatric Department, Fallujah General Hospital, Fallujah City – Anbar Province, 00964, (IRAQ)

²Fallujah General Hospital, Fallujah City – Anbar Province (IRAQ)

E-mail : samiraalaani@hotmail.com; abd69k@yahoo.com

ABSTRACT

We present 3 sporadic cases of congenital left hand Acheiria, a rare congenital defect. In one case (male), left hand Acheiria is associated with left radial hemimelia, in the other 2 cases (both are females), there is only congenital absence of left hand (Acheiria), with completely normal left forearm & other 3 limbs.

The absence of any contributory family or drug history and the normal chromosomal study in the 3 cases lead us to the belief that their occurrence may be linked to environmental contamination.

To the best of our knowledge, there is dearth of informations on these anomalies in the literatures, & their management remains a challenge.

© 2014 Trade Science Inc. - INDIA

KEYWORDS

Acheiria;
Hemimelia;
Fallujah general hospital.

INTRODUCTION

The congenital malformations of upper limbs are not a very frequent condition, for they affect less than 0.2% of born babies. Many of these malformations are not severe, have a minor functional impact and may be surgically treated.

The embriologic development of the upper limb takes place in the early stages, presenting a complete differentiation at week 7 of gestation^[1], Usually, if malformation occurs, it may already be present by the time the mother confirms her pregnancy.

There are many classifications to categorize the various forms of congenital amputation.

According to the International Federation of Societies for Surgery of the Hand^[1] there are 7 groups of malformations:

- failure of formation of parts,
- failure of differentiation (separation) of parts,
- duplication,
- overgrowth,
- undergrowth,
- congenital constriction band syndrome,
- generalized skeletal abnormalities.

Malformations of the first group result in congenital amputations, being the hand and the forearm the most frequent affected. According with the level of malformation they are denominated as:

- * Amelia: total absence of upper limb
- * Hemimelia: absence of forearm and hand.
- * Acheiria: absence of hand.
- * Adactilia: absence of metacarpus and phalanges
- * Aphilangia: absence of all phalanges.

A previous communication reported results of an epi-

demioleological study in Fallujah, Iraq which revealed very high levels of cancer and infant mortality in the period 2005-2010 together with a statistically significant perturbation of the birth sex-ratio of those born from 2005. The authors concluded that some genotoxic exposure had occurred at the same time as the United States-led attacks on Fallujah in April and November 2004^[2].

An attempt to investigate the genetic familial causation of four individual cases of congenital anomaly has subsequently been made^[3] the authors concluded that in these cases there was no familial genetic basis and that sporadic untargeted effects were responsible, causes which they described as epigenetic^[3].

It was clearly of interest then to further examine the evidence of increased infant mortality and congenital conditions in Fallujah and to investigate the environment for possible agents that may explain the increased incidence of birth defects and cancer rate increases. The environmental aspect of the problem was studied in 2010 when hair sample analysis of 52 elements was carried out on the parents of children diagnosed with congenital anomalies^[4]. In addition soil and water samples were analyzed. Results indicated that man-made slightly enriched uranium was present in soil and in the hair of the parents, with a trend of increasing concentration along the hair strands back to 2005 but that no other genotoxic elements were present which could explain the levels of cancer and congenital disease. The question of the incidence and types of congenital anomalies remains^[4].

Then in another pilot study, the numbers of different types of congenital anomaly diagnosed in one of three clinics at Fallujah General Hospital (FGH) over an eleven month period in 2009-2010 have been reported, It was found to be about 144/1000 live births which is much higher than what was reported in other areas in Iraq & it's surrounding countries^[5].

This report details the findings in 2 rare cases of congenital left hand Acheiria, and radial hemimelia & left hand acheiria in a 3rd case.

CASE REPORTS

Case 1

Afemale patient, from Fallujah –Ameriya subdistrict, born by spontaneous vaginal delivery on 6-4-2011,

whose pregnancy and delivery were uneventful, was presented to the neonatal care unit (NCU), in our hospital with complete absence of her left hand (congenitally amputated). She is the 9th child in the family, all of the 8 siblings are normal, the youngest one being 8 yrs old and the patient is the only child born after the year 2004, detailed history was taken from the mother about her pregnancy, there was no chronic or febrile illness, no history of epilepsy, no history of x.ray exposure, no history of drug use like anticonvulsants or any other teratogenic drug. The anomaly didn't diagnosed prenatally, the mother & father are 39 years old and there is no history of consanguinity between them.

There was no prior history of such or other anomaly in the family.

On examination; the left hand was absent (figure 1), there were only remnants of fingers present on the end of the forearm. The left shoulder, elbow, arm and forearm were normal physically and functionally. The other 3 limbs were also completely normal, examination of head, neck, chest including the heart, abdomen and pelvis also revealed no abnormality.

Laboratory work up including complete blood count, CRP, RBS were normal.

Radiography showed absence of left carpal bones and hand (figure 2) with normal forearm bones..

Case 2

Afemale patient delivered by spontaneous vaginal delivery after completing 40 weeks gestation on 26-5-2011, the family live in Fallujah –Nazzal district. She is the 5th child in the family, the other siblings are completely normal and healthy. The mother is 36 years old,

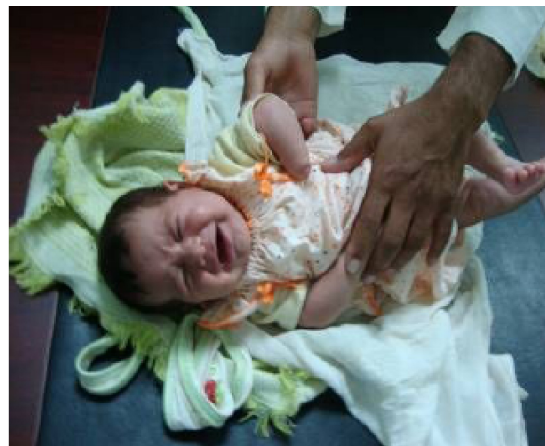
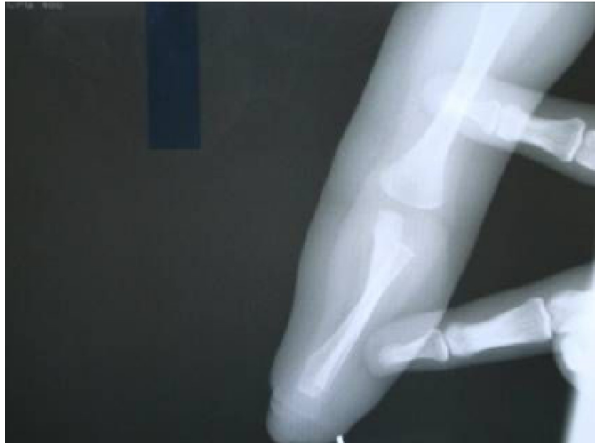
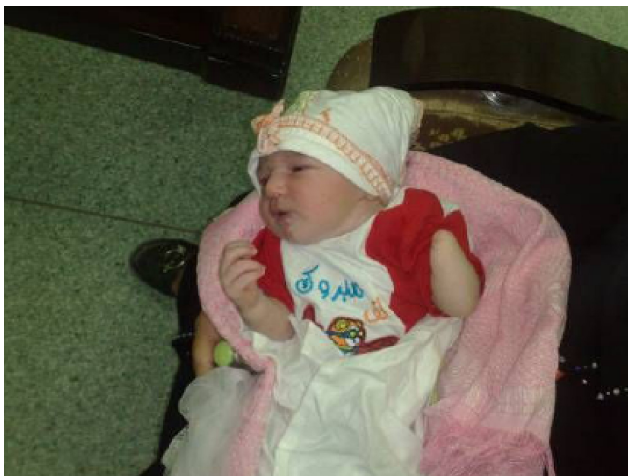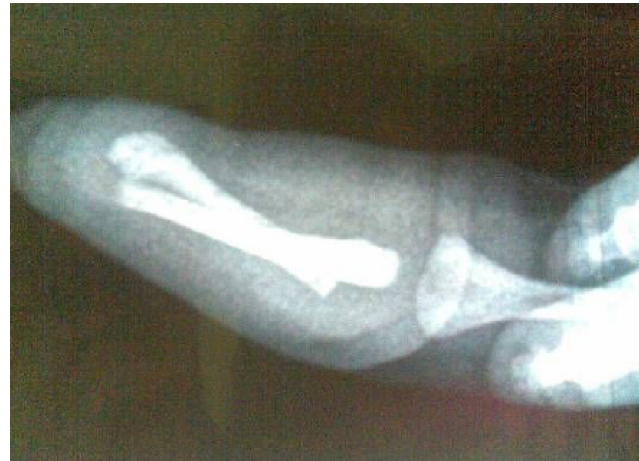Figure 1

Regular Paper**Figure 2**

she gave history of regular antenatal care visits, her pregnancy was normal, she gave no history of any chronic illness like hypertension, diabetes or epilepsy, no history of any febrile illness, no history of x-ray exposure or any drug use apart from tonics... she gave history of having 3 miscarriages during the years 2009 and 2010 (before the birth of this child). The anomaly was not diagnosed prenatally. The father's age is 50 years and there is no consanguinity between the two parents.

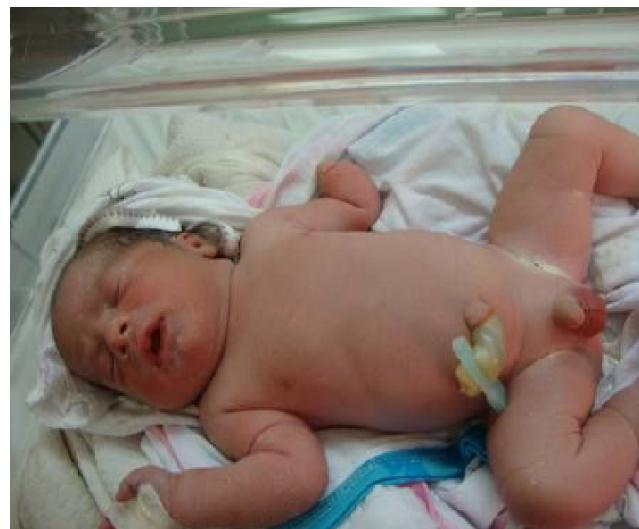There is no previous family history of Acheiria..

On examination ; the left hand is absent from the level of the wrist joint, the left shoulder, elbow, arm & forearm being completely normal in appearance and function. (figure 3) the contralateral upper limb and both lower limbs are normal. head, neck, chest (including heart), abdomen and pelvis were normal. Routine laboratory work up was normal. radiological examination showed absence of left carpal bone and wrist, the radius and ulna were present and normal.(figure 4).

**Figure 3****Figure 4****Case 3**

Amale neonate born by cesarian section after 40 weeks gestation, on 6-7-2011. His family live in Fallujah – Saglaweya subdistrict. He is the 5th child in the family, the older 4 siblings being completely normal. the mother is 35 years old & have gestational hypertension, controlled by diet only, she gave history of hepatitis B virus infection during pregnancy, there is no history of diabetes or epilepsy, no TORCH infection, no history of x-ray exposure or drug use apart from folic acid medication during pregnancy. the anomaly was not diagnosed prenatal ultrasonographic examination. The father's age is 40 years old and the parents are 3rd degree relatives. There is no prior family history of Acheiria or any other anomaly.

On examination; the neonate looks completely normal apart from total absence of the left hand from the

**Figure 5**

level of the wrist joint, and there is remnant of fingers at the end of the forearm (figure 5). The contralateral upper limb and both lower limbs are completely normal. head, neck, chest, heart, abdomen & pelvis are normal.

Laboratory work up including CBC, CRP, RBS, TSB were normal, HBs Ag was -ve.

Radiological examination showed absence of left carpal bones and hand, and also absence of left Radius (left radial hemimelia) (figure 6).

Chromosomal study for the 3 cases was done and

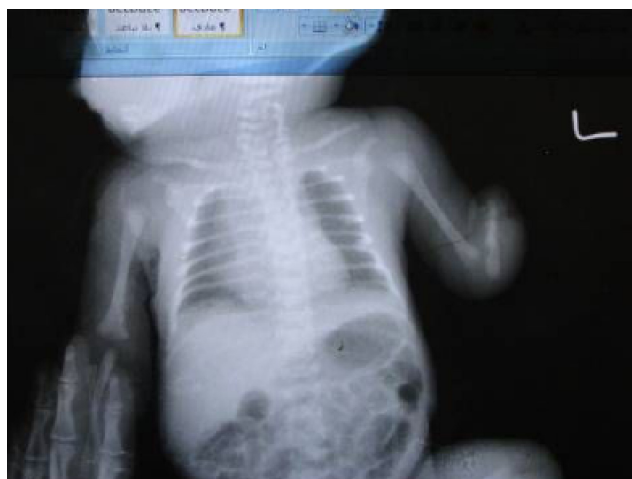

Figure 6

revealed no abnormality (figures 7,8,9)

DISCUSSION

Congenital absence of the hand, Acheiria, is a rare defect occurring in 1:65 000 live births^[6]. It is always unilateral and almost always sporadic; reports of Acheiria recurring in a family are sparse. Familial occurrence of Acheiria and forearm amputation has been recorded, in sibs,^[6] uncle and niece, uncle and nephew, and in a great grandmother and her great granddaughter^[7]. It have been reported also to be caused by the use of Hydantoin anticonvulsant for treatment of maternal epilepsy during pregnancy^[8].

In this report one of the patients (case 3) have absence of his left hand & radius (left Acheiria & radial hemimelia)^[8]. Radial hemimelia is a congenital longitudinal deficiency of the radius bone of the forearm characterized by partial or total absence of the radius. It occurs in 1/30,000-100,000 live births, and is slightly more common in males than in females (sex ratio of

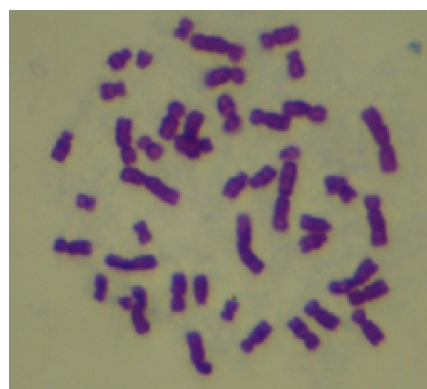


Figure 7 : Chromosomal study case 1

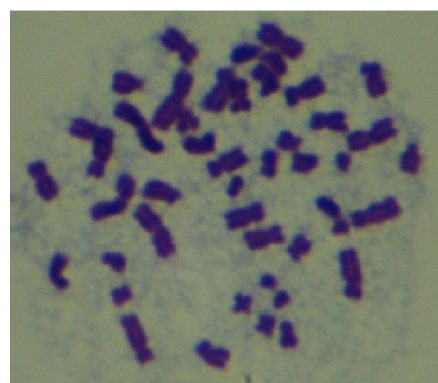


Figure 8 : Chromosomal study case 2

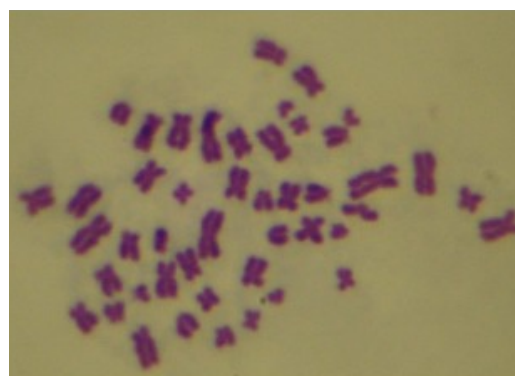

Figure 9 : Chromosomal study case 3

3:2), Radial hemimelia is bilateral in 50% of cases and the right side is more commonly involved than the left (with a ratio of 2:1). Approximately 5-10% of radial hemimelia cases are familial but the etiology remains unknown^[9]. The deformities are believed to develop early in pregnancy, between the 28th and 56th day of gestation.

Maternal drug use (cocaine, thalidomide or valproate), compression of the uterus and vascular injury have been suggested to play a role in the etiopathogenesis of this condition, but these theories have not been proven. Diagnosis is based on clinical examina-

Regular Paper

tion and X rays.

Radial hemimelia can be detected by prenatal ultrasound scan at 20 weeks of gestation^[9]. Considering that the number of live births in our hospital during the year 2011 was 7230, the incidence of Acheiria in our hospital is 4: 10.000 live births compared to the overall incidence of 1: 65.000 livebirths & the incidence of radial hemimelia is 0.5:1000 live births compared to the overall incidence of 1:30.000-100.000 livebirths.

The unilateralism of hemimelia in case 3, have been reported by many authors to occur as much as 80 % of hemimelia & confers better prognosis in term of functionality^[10]. Radial hemimelia is frequently associated with other congenital anomalies or syndromes, including chromosomal anomalies (trisomy 13, 18 and 21), Holt-Oram syndrome, Roberts syndrome, Rothmund-Thomson syndrome, thrombocytopenia-absent radius (TAR) syndrome (in which characteristically the thumb is present), Townes-Brocks syndrome, VACTERL association and Fanconi anemia^[10].

There were no anomalies detected in our 3 patients else where in the body apart from Acheiria, and Acheiria & radial hemimelia (case 3) by clinical examination, laboratory and radiological workup.

CONCLUSIONS AND RECOMMENDATIONS

The absence of contributory family and drug history, normal chromosomal study in the 3 cases, in addition to the non-specific linkage to any environmental factor lead us to the belief that this combination of abnormalities is of sporadic occurrence. These defects could be due to environmental contaminants which are known components of modern weaponry. Investigations of metal contaminants, and elucidation of the types and body burden of metals, combined with simultaneous registry of the population's reproductive history, will allow the identification of families at high risk and will facilitate therapeutic measures to remediate the damages.

CONSET

Conset for publication have been obtained from the 3 sets of parents.

ETHICAL APPROVAL

Ethical approval was granted by the scientific committee in Fallujah hospital

ACKNOWLEDGMENT

The authors should acknowledge the cooperation of the 3 sets of parents for the completion of this report.

REFERENCES

- [1] J.Hib; *Embriología Médica*, México, Editorial Interamericana, McGraw Hill, (1994).
- [2] C.Busby, M.Hamdan, E.Ariabi; Cancer, infant mortality and birth sex-ratio in Fallujah, Iraq 2005-2009. *Int.J.Environ.Res.Public.Health.*, <http://doi.org/ck8j8z>, **7**, 2828-37 (2010).
- [3] S.Alaani, M.Savabieasfahani, M.Tafash et al.; Four polygamous families with congenital birth defects from Fallujah Iraq. *Int.J.Environ.Res.Public Health*, <http://dx.doi.org/10.3390/ijerph8010089>, **8**, 89-96 (2011).
- [4] S.Alaani, M.Tafash, C.Busby et al.; Uranium and other contaminants in hair from the parents of children with congenital anomalies in Fallujah, Iraq. *Confl.Health*, <http://dx.doi.org/10.1186/1752-1505-5-15>, **5**, 15 (2011).
- [5] Samira Alaani, Mohannad A.R.Al-Fallouji, Christopher Busby, Malak Hamdan; Pilot Study of Congenital Anomaly Rates at Birth in Fallujah, Iraq, 2010, *JIMA*, <http://dx.doi.org/10.5915/44-1-10463>, **44**, (2012).
- [6] H.G.Kohler; Congenital transverse defects of limbs and digits. *Arch.Dis.Child*, **37**, 263-76 (2001).
- [7] Harold Chen; *Atlas of genetic diagnosis & counseling*, 407.
- [8] www.orphanet.com
- [9] S.K.Jain, P.K.Lakhatkia; Profile of congenital transverse deficiencies among cases of congenital orthopedic abnormalities. *Journal of Orthopedic surgery*, **10**, 45-52 (2002).
- [10] M.Shafi, J.H.P.Hui; Common paediatric orthopedic problems in the upper limbs. *Singapore Med.J.*, **47**, 654-659 (2006).