



Trade Science Inc.

June 2007

Volume 1 Issue 2

BioCHEMISTRY

An Indian Journal

Regular Paper

BCAIJ, 1(2), 2007 [49-52]

Effects Of Oral Administration Of Ethanolic Leaf Extract Of *Acanthospermum Hispidum* Dc On Carbon Tetrachloride Induced Acute Liver Injury In Rats



Corresponding Author

T.I.Edewor
Department Of Pure And Applied Chemistry,
Ladoke Akintola University Of Technology,
Ogbomoso, (NIGERIA)
Ph.: 234-8037272625
E-mail: ibitheresa@yahoo.com

Received: 18th February, 2007

Accepted: 23rd February, 2007

Web Publication Date : 11th March, 2007



Co-Authors

A.A.Olajire¹ L.E.B.Olaniyan²,
¹Department Of Pure And Applied Chemistry, Ladoke Akintola
University Of Technology, Ogbomoso, (NIGERIA)
²Department Of Biochemistry, Ladoke Akintola University Of
Technology, Ogbomoso, (NIGERIA)

ABSTRACT

The effects of administering the ethanolic leaf extract of *Acanthospermum hispidum* dc on patients of hepatitis were studied on acute hepatitis induced by carbon tetrachloride (20% CCl₄/olive oil, 1.5 ml/kg, p.o) in rats. These effects were monitored by estimating the serum transaminases levels and the histopathological changes in the livers of experimental rats. The pre-treatment of the animals with *Acanthospermum hispidum* dc leaf extract (0.3-2.0 g/kg orally) significantly elevated the activities of the serum transaminases as well as the hepato-toxin-induced histopathological changes in the livers of the experimental rats. But in cases of no hepatitis, the observed effect of the leaf extract was normal like that of the control.

© 2007 Trade Science Inc. - INDIA

KEYWORDS

Acanthospermum hispidum dc;
Hepatitis.

INTRODUCTION

In recent years following the demonstration of the presence of active principles against many diseases and infections in a variety of plant extracts, there has been a great surge of public interest in the use of herbs and plants. Some scientists have viewed this

phenomenon as a modern herbal 'renaissance'^[3].

Though, pharmaceutical industries are moving towards synthetics and biotechnology research in search of novel medicine in the 21st century; consumers are expressing a greater awareness of the risks of using synthetic products^[2,6]. Therefore, attention is now focused on the various aspects of toxicity of such plants

Regular Paper

extracts^[1] in order to have a good understanding of the safety potentials and level of toxicity, if any.

Acanthospermum bispidium dc is a medicinal plant commonly known as 'ewe onitan meta' in Western Nigeria. The leaves are used locally for the treatment of acute tuberculosis, various types of cough, diarrhea, dysentery, typhoid and pneumonia.

There is no record of its scientific study on its effects on liver. The aim of the present study was to investigate the effects of the ethanolic extract of *Acanthospermum bispidium* dc in an experimental model of acute liver injury in rats. In that hepatitis patients who have also contracted any of the diseases that are curable by the use of the leaf extract will be handled with extreme care in order not to alleviate the hepatitis condition thereby leading to death of the patient. Therefore this study describes the effects of *Acanthospermum bispidium* dc in an animal model of hepatotoxicity.

EXPERIMENTAL

Sampling

The plant was collected from an herbal health practitioner in Ogbomoso, Nigeria and taken to biology laboratory of Ladoké Akintola University of Technology, Ogbomoso, Nigeria for identification.

Preparation of plant leaf extract

The leaves were air dried in the laboratory for a period of two weeks. It was then ground into fine powder using sterilized food blender and stored in a sealed plastic container until when required. The leaves were extracted by adding 500g of it into one liter of ethanol.

Experimental animals

White albino rats (Sprague dawley) weighing approximately 200g were obtained from the animal breeding unit of the department of Animal Production and Health, Ladoké Akintola University of Technology, Ogbomoso, Nigeria. The animals were housed in clean cages and fed with rat pellets and water ad libitum. The animals were then divided into 6 groups of 10 rats each. They were allowed to acclimatize to their new environment for two weeks

before administration of the leaf extract.

Chemicals and reagents

Carbon tetrachloride (Wako Pure Chemical Industries Ltd.). Kits for determining sGPT (B 8122) and sGOT (B 8120) activities. All other chemicals were of reagent grade and were used without further purification.

Acute toxicity test

The rats were divided into 6 groups of 10 animals each. The animals were then treated with graded doses (0.3, 0.5, 1.0, 2.0, 5.0 and 10.0g/kg) of the extract by oral administration (p.o) and the median lethal dose (LD₅₀) was determined as described by^[4]. These animals were continually observed for general symptoms of toxicity and mortality after 72 hours.

CCl₄-Induced hepatotoxicity in rats

The rats were divided into six groups of 10 rats and CCl₄ (1.5ml/10ml/kg, in olive oil) was administered to animals of the first five groups orally. The sixth group received olive oil alone (10ml/kg, p.o) and was used as a vehicle control. The extracts (0.3, 1.0 and 2.0g/10ml.kg, were fed to the rats in groups C, D, and E respectively three times, each at 6, 24 and 42 hour- time periods before CCl₄ administration; while the remaining two groups, i.e. one treated with CCl₄ (group B) and the other vehicle (group A) treated only, were given no more treatment. All animals were killed 48h after CCl₄ administration, blood was withdrawn from the carotid artery and the sera were separated for each study.

Assessment of liver function

The collected blood was centrifuged at 3000rev/min, using a centrifuge (centurion model GP(CD295-30)) at 4°C for 10 mins to separate the sera. The activities of glutamate-oxalate-transaminase (sGOT) and glutamate-pyruvate-transaminase (sGPT) were measured, using the method described by Mohun and Cook. Protein concentration was determined by the Biuret method. Spectronic model (Bausch and Lomb, USA) was used for all measurements.

Histopathological observations

After blood draining, liver sections were taken from each lobe of the liver. The tissue was fixed in

10% neutral formalin, dehydrated with different ethanol solutions (50-100%) and embedded in paraffin. It was then cut into 4-5 μ m thick sections, stained with haematoxylin-eosin and observed under a photomicroscope.

Statistical analysis

Data were expressed as mean \pm SEM(n=6) and statistically assessed by one-way analysis of variance (ANOVA). The difference between the drug treated animal and control groups was evaluated by student's t-test.

RESULTS AND DISCUSSION

The ethanolic extract of *Acanthospermum hispidum* dc was found to be safe for further biological studies as no lethality was observed at doses as high as 10g/kg p.o in the rats. TABLE 1 shows the serum enzyme levels of rats in the *Acanthospermum hispidum* dc treated and other groups. Administration of CCl₄ resulted in a marked increase of serum GOT and GPT, which were significantly different from those of the vehicle control (group B vs A in figure 1). Treatment of rats with the ethanolic leaf extract of *Acanthospermum hispidum* dc caused an increase of sGOT and sGPT induced by CCl₄ - intoxication.

The histopathological changes associated with the unhepatoprotective activity of the *Acanthospermum hispidum* dc extract basically support the results of the serum enzymes.

The liver of the CCl₄ intoxicated rats showed de-

TABLE 1: Effect of oral administration of *Acanthospermum hispidum* dc on some selected enzymes

Group	sGOT(1u/L)	sGPT(1u/l)
Control (NS + vehicle)	133.5 \pm 1.41	36.3 \pm 1.6
CCl ₄ intoxication (NS+ CCl ₄ (20% CCl ₄ /olive oil, 1.5ml/kg, (p.o)	395.2 \pm 61.6 ^a	112.2 \pm 13.8 ^a
Treatment		
AH (0.3g/kg) + CCl ₄	396.5 \pm 20.5 ^b	114.8 \pm 6.5 ^b
AH (1.0g/kg) + CCl ₄	399.8 \pm 15.6	118.2 \pm 5.2 ^b
AH (2.0g/kg) + CCl ₄	405.8 \pm 25.2 ^c	130.5 \pm 8.1 ^c
AH alone	135.8 \pm 2.51	37.9 \pm 1.4

Each value represents mean \pm SEM (n = 6). Student's t - test was performed.

^ap < 0.01 significantly different from control group; ^bp < 0.01

^cp < 0.05 significantly different from CCl₄ -intoxicated group; NS: Normal saline

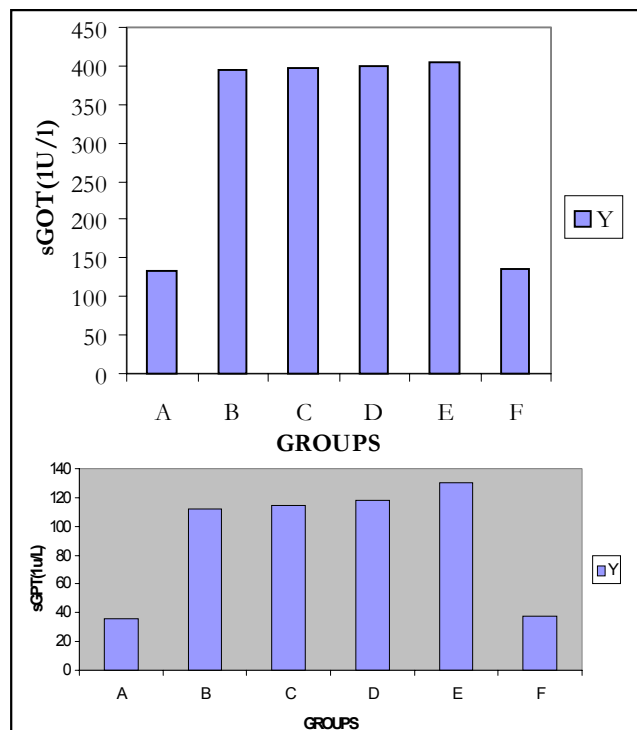


Figure 1: The prophylactic effects of *Acanthospermum hispidum* dc leaf extract on sGOT and sGPT in CCl₄ -treated rats. A: vehicle control; B: CCl₄/ olive oil(1.5ml/kg); C: AH - 0.3g/kg + CCl₄; D: AH - 1.0g/kg + CCl₄; E: AH - 2.0g/kg + CCl₄; F: AH alone. Values represent the mean \pm SEM of ten rats. *p < 0.005, **p < 0.01 (student's t - test, compared with B, p < 0.01 (compared with A).

Each value represents mean \pm SEM (n = 6). Student's t - test was performed. ^ap < 0.01 significantly different from control group; ^bp < 0.01. ^cp < 0.05 significantly different from CCl₄ - intoxicated group; NS: Normal saline

formity of the sinusoids, which is responsible for the hemorrhage seen in the tissue. There was broad infiltration of the lymphocytes and kupffer cells around the central vein and loss of cellular boundaries, massive fatty change and necrosis.

The histopathological pattern of the livers of the rats treated with ethanolic leaf extracts of *Acanthospermum hispidum* dc showed almost the same pattern with that of the CCl₄ - intoxicated ones but the cells were seen to be highly extra hepatic cholestasis. The centre of the cells was filled with concentrated bile pigment, which is responsible for the degeneration of the liver cells. The kupffer cells were not seen at all. The central hepatic vein was heavily hemorrhaged. CCl₄ is metabolized by the mixed-function oxidase system in the endoplasmic reticulum of the

Regular Paper

liver. The carbon-chloride bond cleavage results in the formation of trichloromethyl free radicals ($*\text{CCl}_3$), which are highly unstable and immediately react with membrane components^[7]. Covalent bonds are formed with unsaturated fatty acids resulting in the production of chloroform and lipid radicals. The lipid radicals then react with molecular oxygen, which initiates the peroxidative decomposition of phospholipids in the endoplasmic reticulum. This peroxidation process results in the release of soluble products that may affect other membranes such as cell membrane^[5].

Our study indicated that treatment with the herbal extract of *Acanthospermum hispidum* dc appeared to enhance the CCl_4 - induced hepatotoxicity as monitored by the sGOT and sGPT.

The present study has demonstrated that the ethanolic leaf extract of *Acanthospermum hispidum* dc enhances the damage of an already damaged liver but has no effect on normal liver.

ABBREVIATIONS

- (1) sGOT-Serum glutamate-oxalate-transaminase.
- (2) sGPT-Serum-pyruvate-transaminase.
- (3) NS-normal saline.
- (4) AH-Acanthospermum hispidum.
- (5) CCl_4 -Carbon tetrachloride.
- (6) $*\text{CCl}_3$ -trichloromethyl radical.

REFERENCES

- [1] J.O.Adebayo, M.T.Yakubu, E.C.Egwin, B., V.Owoeye, B.U.Enaibe; Journal of Ethnopharmacol **88**, 69-72 (2003).
- [2] J.Greenwald; Herbal Healing.timemagazine. nov. 23, **152**, No. 21, 58-69 (1998). www.time.com/time/magazine/1998/dom/981123/cover/. Html (08/01/2001).
- [3] A.Lewington; 'A Review of the Importation of Medicinal Plants and Plant Extracts into Europe', TRAF-FIC International, Cambridge, UK (1993).
- [4] J.T.Litchfield, F.A.Wilcoxon; Pharmacol.Exp. Ther., **96**, 99-113 (1949).
- [5] J.Packer, T.Slater, R.Wilson; Life Sci., **23**, 2617-2620 (1978).
- [6] P.P.Principle; Valuing Diversity of Medicinal Plants. 79-124 in 'Conservation of Medicinal Plants', by O.Akerele, V.Heywood, H.Synge, eds. Cambridge University Press, Cambridge, UK, (1991).
- [7] R.O.Recknagel, E.Glende; Crit.Rev.Toxicol., **2**, 263-297 (1973).
- [8] Shieh-Qing Wan, Syh-Nih-Sann; Ethnopharmacol, **55**, 212-222.
- [9] C.C.Tsai, C.T.Kao, C.T.Hsu, C.C.Lin, J.G.Lin, Syh-Mo-Yiin, Guihi-Fuling-Wan; 'Evaluation of Four Prescriptions of Traditional Chinese Medicine', (1997).