



Antihyperglycemic, antihyperlipidemic and antioxidative potential of *Hydroclathrus clathratus*

M.A.Nagy^{1*}, S.A.Mohamed²

¹Chemistry department, Faculty of science, Beni-Suef University, (EGYPT)

²Biochemistry department, Faculty of Medicine, Al azher university, (EGYPT)

E-mail : Nagy_bio@yahoo.com

ABSTRACT

Alloxan administration in male albino rats, induced diabetes by increasing blood glucose concentration and reducing hepatic glycogen content as compared to normal control group. Besides, serum lipid profile parameters such as total-cholesterol, triglyceride, low-density lipoprotein and very low-density lipoprotein-cholesterol were also elevated, whereas, the level of high-density lipoprotein-cholesterol was reduced significantly ($P < 0.05$) in diabetic rats. Treatment of diabetic animals with hot aqueous extract of *Hydroclathrus clathratus* for 30 days, significantly lowered blood glucose level, elevated hepatic glycogen content and maintained body weight and lipid-profile parameters towards near normal range..

Declined activity of antioxidant enzymes and concentration of non-enzymatic antioxidants were also normalized by HCE treatment, thereby reducing the oxidative damage in the tissues of diabetic animals and hence indicating the anti-diabetic and antioxidant efficacy of the extract.

Biochemical observations were further substantiated with histological examination of liver and pancreas. © 2014 Trade Science Inc. - INDIA

KEYWORDS

Hydroclathrus clathratus;
Diabetes mellitus;
Oxidative stress;
Antidiabetic;
Antioxidant.

INTRODUCTION

The increasing incidence of diabetes represents an enormous socio-economic burden in the developing countries. The World Health Organization estimates that over 300 million people worldwide will have (Diabetes mellitus) DM by the year 2025 with alarming proportions from developing countries^[1].

DM is a chronic disease caused by inherited or acquired deficiency in insulin secretion and by decreased responsiveness of the organs to secrete insulin. There are two main forms of diabetes. Type 1 diabetes is due

primarily to autoimmune-mediated destruction of pancreatic islet β -cells, resulting in dramatic insulin deficiency^[2].

Oxidative stress represents a significant mechanism for the destruction of cells that can involve apoptotic cell injury and apoptosis in a variety of cell types that involve endothelial cells (ECs), cardiomyocytes, and smooth muscle cells through multiple cellular pathways. The production of Reactive oxygen species (ROS) can lead to cell injury through a number of processes that involve the peroxidation of cellular membrane lipids^[3].

Oxidative stress forms the foundation for the in-

Regular Paper

duction of multiple cellular pathways that can ultimately lead to both the onset and subsequent complications of DM. Diabetics and experimental animal models exhibit high oxidative stress due to persistent and chronic hyperglycemia, which thereby depletes the activity of antioxidative defense system and thus promotes de novo free radicals generation^[4a]. The source of oxidative stress is a cascade of ROS leaking from the mitochondria. This process has been associated with the onset of type 1 diabetes (T1DM) via the apoptosis of pancreatic β -cells, and the onset of (T2D) via insulin resistance^[5].

In recent years due to the adverse effects of synthetic hypoglycemic drugs, interests in alternate therapeutic approach have become very popular. Nowadays, herbal drugs are gaining popularity in the treatment of diabetes and its complications due to their efficacy, low incidence of side effects and low cost^[6].

Egypt has long seashores represented by the Mediterranean and the Red Sea. These shores contain a national wealth of marine organisms, especially algae. An increasing number of studies have demonstrated that certain compounds produced by marine organisms have potential therapeutic uses.

Brown marine algae to be rich sources of antioxidant compounds with potential free radical scavenging for the prevention and treatment of various diseases caused by oxidative damage. Fucoindans, polysaccharides containing substantial percentages of L-fucose and sulfate ester groups, are constituents of brown algae that have numerous other biological properties such as antioxidant, anti-inflammatory immuno-modulatory and apoptosis-inducing activities^[7a].

Hydroclathrus clathratus (C. Agardh) Howe is brown marine algae and considered to be a traditional drug and health food in Korea, Japan and China. Hot water extract of *H. clathratus* (HCE) is rich in of water-soluble sulfated polysaccharides that exhibit valuable biological effects as anticancer, anti-herpetic and anti-coagulant activities^[8].

But till date, It is the first study about the anti-diabetic and antioxidant potential of *H. clathratus*. In the present study, the effect of 30 day chronic oral treatment with HCE with a dose of 400 mg/kg body wt on diabetes and resultant oxidative stress was investigated by evaluating its antihyperglycemic, antihyperlipidemic and antioxidative properties in alloxan induced diabetic

rats confirmed by histological examination of Pancrea and liver of alloxan induced diabetic rats.

MATERIALS AND METHODS

Chemicals

Alloxan monohydrate was purchased from sigma Fine chemicals. All other chemicals used for this study were of analytical grade and obtained from Stanbio Laboratory USA Kits. Kits for the estimation of total cholesterol, triglyceride and HDL-cholesterol were purchased from from Diamond Diagnostic Egypt.

Preparation of extract

Hydroclathrus clathratus was collected from El Zafrana, Gulf of Suez. About 100 g of the fresh alga, corresponding to 10 – 12 g of dry alga material was homogenized in 500 ml hot double distilled water. The mixture was clarified by filtration using Whatman No.1 filter paper and the light brown extract resulted. The water extract of *H. clathratus* were sterilized by filtration and autoclaving, respectively.

Animal care and monitoring

Healthy male albino rats (5-7 months old, weighing 190-210 g) were procured from Faculty of Agricultural, El Minia University, Egypt. They were housed under standard laboratory conditions of light (12:12 h L: D cycle), temperature ($23 \pm 2^\circ\text{C}$) and relative humidity ($55 \pm 5\%$). The animals were provided standard rat pellet feed and tap water ad libitum. Maintenance and treatment of all the animals was done in accordance with the principles of Institutional Animal Ethics Committee constituted as per the directions of the Committee for the Purpose of Control and Supervision of Experiments on Animals, Egypt.

Induction of diabetes and treatment with drugs

For the present study, animals were divided into following 3 groups:

NC (normal control), DC (diabetic control) and HCE (diabetic + *H. clathratus* extract treated). After fasting for 18 hours, rats of group DC, HCE were made diabetic by a single intra-peritoneal injection of alloxan monohydrate, 150 mg/kg body wt, freshly dissolved in normal saline^[9]. Subsequent to alloxan administration

the rats had free access to food and water and were provided with 50% glucose solution to drink overnight to counter HCE induced hypoglycemic shock. One week after alloxan injection, the fasting blood glucose (FBG) concentration was determined by means of one touch ultra glucometer (Johnson & Johnson Company, USA) and compatible blood glucose strips^[10]. Rats showing fasting blood level greater than 140 mg/dl were considered diabetic and selected for treatment with hot water extract of *Hydroclathrus clathratus* (HCE) (400 mg/kg body wt.). HCE was administered orally, once in a day for 30 days.

Biochemical estimations in blood and serum insulin

Fasting blood glucose (FBG) concentration of all the four experimental groups was determined by glucometer during different phases of the experiment by withdrawing blood from the tail vein. Serum insulin was assayed in the Radioactive Isotopes Unit, Central Department of Scientific Analysis and Test, National Research Center (Dokki, Giza) by radioimmunoassay kits of DPC (Diagnostic Products Corporation, Los Angeles, USA) [coat-A-count]^[11].

For estimating serum lipid profile, serum was isolated from the blood collected by cardiac puncture under mild ether anesthesia from overnight fasted rats on 30th day of HCE treatment and serum total cholesterol (TC), triglyceride (TG) and HDL-cholesterol were estimated by using diagnostic kits (Erba Mannheim Cholesterol kit, Transasia Bio-Medicals Ltd., Daman).

Biochemical estimation in tissue homogenates

Liver and pancreas were removed, freed from adhering tissues and washed with ice-cold normal saline solution (0.9%). Weight of all the organs was taken only after drying the tissue. 1 g tissue was homogenized in 10 ml of 0.2 M tris-HCl with the help of homogenizer. The homogenate was filtered and then centrifuged at 10,000 rpm for 20 minutes at 4°C. The supernatant obtained was used for estimation of superoxide dismutase (SOD)^[12], catalase (CAT)^[13], glutathione peroxidase (GSH-Px)^[14], reduced glutathione (GSH)^[15], thiobarbituric acid reactive substances (TBARS)^[16], Hepatic G-6-Pase^[17] and glycogen phosphorylase^[18].

Histopathological examination of tissues

Histopathological examination of pancreas

Some pancreas were cleaned and fixed in 10% neutral buffered formalin solution. After dehydration in graded ethanol solutions and in toluene, they were embedded in parafin. Sections of 3–5µm thickness were stained with hematoxylin and eosin (H.E.) for histopathological examination.

Histopathological examination of liver

Some liver were cleaned and fixed in 10% neutral buffered formalin solution. After dehydration in graded ethanol solutions and in toluene, they were embedded in paraffin. Sections of 3–5µm thickness were stained with hematoxylin and eosin (H.E.) for histopathological examination. Other sections were stained with (Periodic acid staining) PAS Stain and Trichome stain for histopathological examination of glycogen and collagen respectively.

Statistical analysis

Results are expressed as mean ± Standard Error of Mean (SEM). Statistical analysis was performed using one-way Analysis of Variance (ANOVA) followed by Tukey's post-hoc multiple comparison test using SPSS (version 16.0) and student's 't'-test using SigmaPlot (version 8.0). The values of P<0.05 were considered as statistically significant.

RESULTS

Effect on body weight

All animals treated with alloxan in diabetic control group (DC) revealed a significant (P<0.05) loss in body weight, which was persistently observed till the end of

TABLE 1: Effect of 30 days treatment of *H. Clathrus* hot water extract on body weight and FBG level in alloxan-induced diabetic rats; Values are mean ± SEM of 7 observations.

Parameters	NC	DC	DC+HCE
Body Weight (g)	190±12.2	165.2±11.3***a	234.5 ^b
FBG Level (mg/dl)	121.12±2.3	465±41.8***a	241±18.9 ^b
Serum insulin levels (ng/ml)	1.18±0.07	0.48±0.07***a	1.06±0.06 ^b

Values significantly different compared to normal P*** < 0.01. Values are expressed as means ± SEM. Means not sharing common letter are significantly different (p < 0.05).

Regular Paper

TABLE 2: Effect of 30 days treatment of *H. Clathrus* hot water extract on activity of hepatic glycogen phosphorylase and hepatic glucose-6- phosphatase (G6Pase) content in alloxan-induced diabetic rats. Values are mean \pm SEM of 7 observations

Group	Hepatic glycogen phosphorylase	Hepatic glucose-6-phosphatase (G6Pase)
	(mU/g tissue)	(mU/g tissue)
Normal Control (NC)	0.95 \pm 0.13	1.42 \pm 0.21
Diabetic Control (DC)	6.47 \pm 0.76 ^{***a}	8.45 \pm 0.97 ^{***a}
Diabetic+HCE (DC +HCE)	3.67 \pm 0.27 ^b	4.27 \pm 0.45 ^b

Values significantly different compared to normal P** * < 0.01. Values are expressed as means \pm SEM. Means not sharing common letter are significantly different (p < 0.05).

TABLE 3: Effect of 30 days treatment of *H. Clathrus* hot water extract on serum lipid profile in alloxan-induced diabetic rats. Values are mean \pm SEM of 7 observations.

Parameters	NC	DC	HCE
TC	87.2 \pm 8.4	163.2 \pm 7.9 ^{***a}	96.4 \pm 6.3 ^b
TG	74.2 \pm 6.8	178.2 \pm 10.4 ^{***a}	103.7 \pm 8.3 ^b
HDL	63.2 \pm 5.7	39.3 \pm 4.5 ^{***a}	50.2 \pm 3.9 ^b
LDL	13.5 \pm 7.3	53.2 \pm 4.8 ^{***a}	26.3 \pm 11 ^b

Values significantly different compared to normal P** * < 0.01. Values are expressed as means \pm SEM. Means not sharing common letter are significantly different (p < 0.05).

the study period (TABLE 1). Weight reduction induced by diabetes in group (HCE) was cured by HCE treatment.

Effect on fasting blood glucose level, serum insulin

Alloxan injection to DC and HCE groups resulted in a significant (P<0.05) increase in blood glucose level as compared to normal control group A. Treatment with *H. Clathrus* hot water extract (HCE) for 30 days significantly reduced the glucose after 30 days of treatment (TABLE 1).

Alloxan injection to DC and HCE groups resulted in a significant (P<0.05) decrease in serum insulin level as compared to normal control group A. Treatment with *H. Clathrus* hot water extract for 30 days significantly enhanced the insulin release after 30 days of treatment (TABLE 1).

Effect of HCE on activity of hepatic glycogen phosphorylase and hepatic glucose-6- phosphatase in alloxan induced diabetic rats

Activity of hepatic glycogen phosphorylase and hepatic glucose-6- phosphatase increased significantly in diabetic control group (DC) compared to normal control group (NC). However, treatment with *H.*

TABLE 4: Effect of 30 days treatment of *H. Clathrus* hot water extract on antioxidative status in alloxan-induced diabetic rats. Values are mean \pm SEM of 7 observations.

Parameters	NC	DC	HCE
Hepatic GSH ¹	16.23 \pm 1.23	10.23 \pm 0.69 ^{***a}	34.89 \pm 1.88 ^b
Hepatic TBARS ²	46.39 \pm 5.2	1248 \pm 133 ^{***a}	542.36 \pm 29.8 ^b
Hepatic CAT ³	234.25 \pm 9.58	174.36 \pm 11.89 ^{***a}	248.69 \pm 17.06 ^b
Hepatic GSH-Px ⁴	681.23 \pm 26.36	453.69 \pm 33.26 ^{***a}	648.32 \pm 30.41 ^b
Hepatic SOD ⁵	308.23 \pm 30.25	235.16 \pm 23.06 ^{***a}	299.32 \pm 23.28 ^b
Pancreatic GSH ¹	14.25 \pm 0.69	8.36 \pm 0.26 ^{***a}	30.44 \pm 2.48 ^b
Pancreatic TBARS ²	96.23 \pm 13.26	452.26 \pm 17.59 ^{***a}	340.26 \pm 21.23 ^b
Pancreatic CAT ³	265.12 \pm 15.59	165.24 \pm 8.49 ^{***a}	345.29 \pm 19.65 ^b
Pancreatic GSH-Px ⁴	714.26 \pm 51.23	478.23 \pm 34.36 ^{***a}	671.23 \pm 60.36 ^c
Pancreatic SOD ⁵	321.02 \pm 31.20	293.58 \pm 24.19 ^{***a}	341.25 \pm 30.69 ^b

¹mg/gm tissue, ²nM TBARS/mg protein, ³ μ moles H₂O₂ decomposed/min/mg protein, ⁴ μ g GSH consumed/min/mg protein, ⁵Units/min/mg protein; Values significantly different compared to normal P** * < 0.01. Values are expressed as means \pm SEM. Means not sharing common letter are significantly different (p < 0.05).

Clathrus hot water extract for 30 days significantly (P<0.05) decreased activity of hepatic glycogen phosphorylase and hepatic glucose-6- phosphatase as compared to DC (TABLE 2).

Effect on serum lipid profile

Compared to normal control group (NC), the level of serum TC, TG, LDL cholesterol was significantly (P<0.05) increased whereas the level of HDL-cholesterol was significantly (P<0.05) reduced by in untreated diabetic rats (DC) (TABLE 3). After treatment of group HCE with *H. Clathrus* hot water extract for 30 days, the level of serum TC, TG, and LDL -cholesterol reduced significantly (P<0.05) whereas, the level of serum HDL-cholesterol was significantly increased.

Antioxidative status

It was observed that after inducing diabetes, the

level of hepatic and pancreatic GSH content decreased significantly in diabetic control group (DC) as compared to normal control group (NC). Treatment of group HCE with H. Clathrus hot water extract for 30 days significantly ($P < 0.05$) increased the tissue's GSH level as compared to DC (TABLE 4).

Data of the present study also revealed a significantly ($P < 0.05$) increased concentration of TBARS, a measure of lipid peroxidation, in the hepatic and pancreatic tissues of diabetic rats. However, a significant reduction in the level of TBARS was observed in the liver and pancreas of HCE treated group (HCE) (TABLE 4). Induction of diabetes significantly ($P < 0.05$) reduced the activity of catalase and GSH-Px in liver, pancreas and kidney of DC as compared to NC. However, 30 days treatment of diabetic animals with HCE increased the activity of these enzymes in all the tissues (TABLE 4). Alloxan injection significantly ($P < 0.05$) decreased the activity of SOD in liver and pancreas 30 days treatment with HCE significantly improved the activity of SOD in the tissues of liver and pancreas in HCE (TABLE 4).

Effects of HCE on alloxan-induced histological changes in pancreas

The results of H. Clathrus in histopathologic examination are shown in Figure 1. As revealed in (Figure 1b), a clear decrease in the area occupied by the β -cells was observed in the pancreatic sections of alloxan-induced diabetic rats. Treatment with HCE showed a slight hypertrophy of Langerhans islets in pancreas compared to alloxan treated rats (Figure 1c) revealing the protective effect of HCE.

Effects of HCE on alloxan-induced histological changes in liver (H&E Stain)

The results of H. Clathrus in histopathologic examination are shown in Figure 2. As revealed in (Figure 2b), kupffer cells activation, dilation and congestion of central vein and hepatic sinusoids were observed in the hepatic sections of alloxan-induced diabetic rats. Treatment with HCE showed improvement of in liver compared to alloxan treated rats (Figure 2c) revealing the hepatic protective effect of HCE.

Effects of HCE on alloxan-induced histological changes in liver (PAS)

The results of H. Clathrus in histopathologic examination are shown in Figure 3. As revealed in (Figure 3b), variable sized positive Pas glycogen particles distributed throughout the hepatocytic cytoplasm in the hepatic sections of alloxan-induced diabetic rats. Treatment with HCE showed a moderate PAs particles distributed throughout the hepatocytic cytoplasm compared to alloxan treated rats (Figure 3c).

DISCUSSION

Glucose is the key physiological regulator of insulin secretion; indeed, short-term exposure of β -cells to increasing glucose concentrations induces proliferation in a concentration-dependent manner. In addition to its effect on β -cell turnover, hyperglycemia also impairs β -cell secretory function. This glucotoxic effect is evident before apoptosis leads to a significant decrease in β -cell mass^[19].

Alloxan-induced diabetic rats exhibited severe glucose intolerance and metabolic stress as well as hyperglycemia due to a progressive oxidative insult interrelated with a decrease in endogenous insulin secretion and release. Treatment with antidiabetic drugs based on their pancreatic antioxidant activity might be a protective strategy for protecting β -cell due to disproportionate generation of free radicals^[20].

The present investigation indicated that a single dose of alloxan (150 mg/kg) intraperitoneally to adult male albino rats (190-210g) was suitable to induce histological changes of the islets of Langerhans characterized appearance, hypoinsulinemia and hyperglycemic state. The present dose as well as the observed histopathological and biochemical manifestations agree with the previous literature^[21].

A gradual loss of β -cells due to apoptosis significantly hinders insulin production and inhibits cell viability. During apoptosis, cells shrink; chromatin condenses; DNA is cleaved into pieces at inter nucleosomal regions. A proactive way to increase β -cell viability is to decrease apoptosis level in order to retain the cell population and increase insulin production^[22].

Exposure of islets to alloxan shows significantly increased formation of peroxynitrite, NO and ROS with markedly elevated lipid peroxidation and reduced cell viability. Islets exposed to alloxan also show significantly

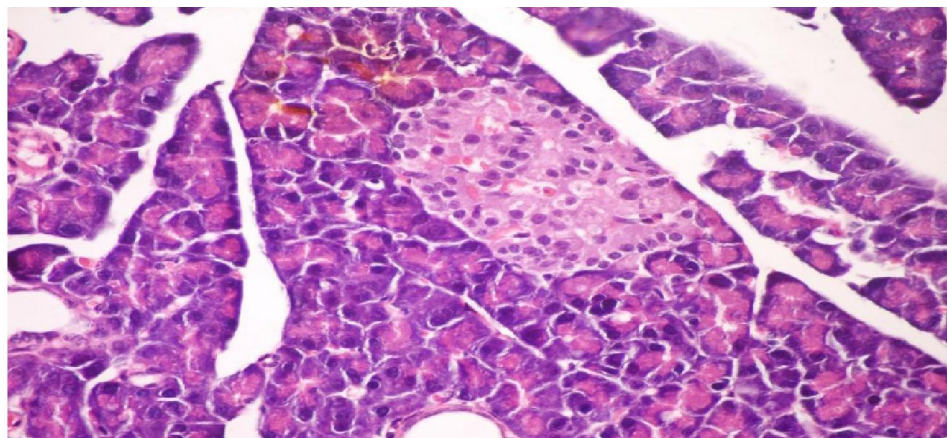
Regular Paper

Figure 1.a: Pancreatic tissue of normal male albino rats. The pancreas is subdivided by septa into pancreatic lobules. The exocrine portion of the pancreas consists of pancreatic acini while endocrine portion consists of islets of Langerhans (H& E x 400).

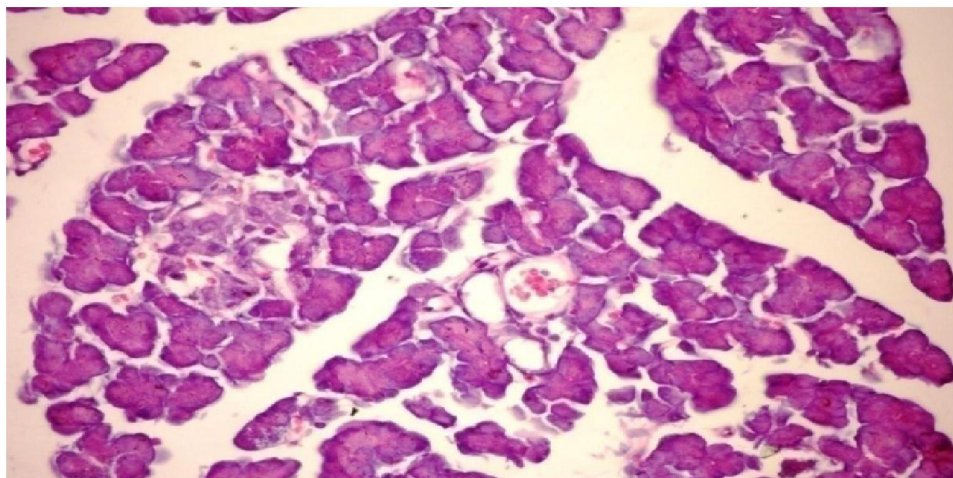


Figure 1.b: Pancreatic tissue of diabetic rats. Normal architecture of the islets is disrupted. Islets of Langerhans exhibited hydrophobic cells, necrotic cells, vacuolizations and irregular hyperchromic nuclei (H& E x 400).

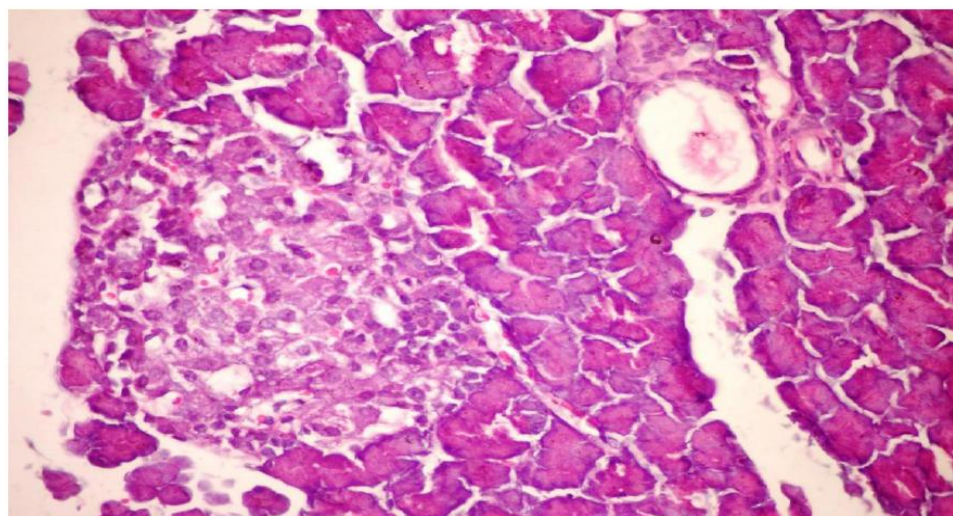


Figure 1.c: Pancreatic tissue of diabetic rats treated with HCE (orally 400 mg/kg body weight of rats daily for 30 consecutive days) showing hypertrophy and vacuolations of B cells of islets of Langerhans (H& E x 400).

Figure 1 : Histological changes in pancreases of diabetic rats (H&E)

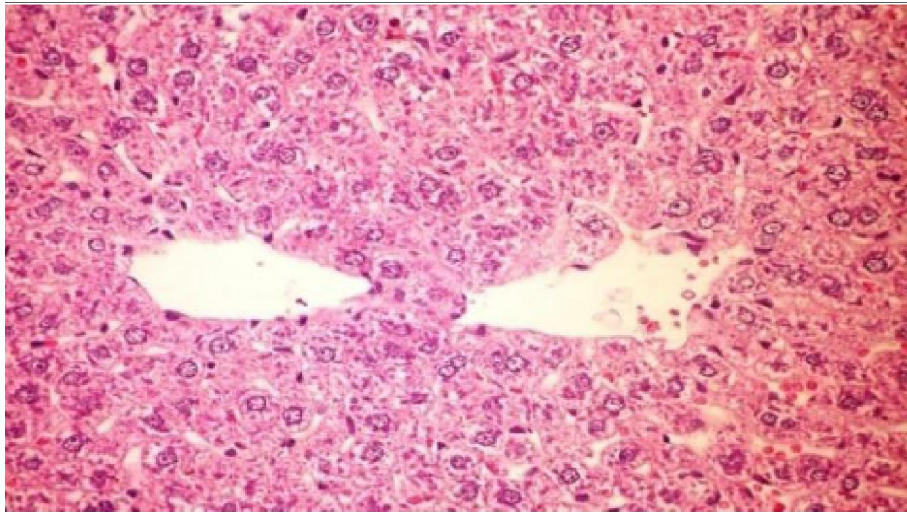


Figure 2.a : Liver of normal control rat showing the normal histological structure of hepatic lobule (H& E x 400)

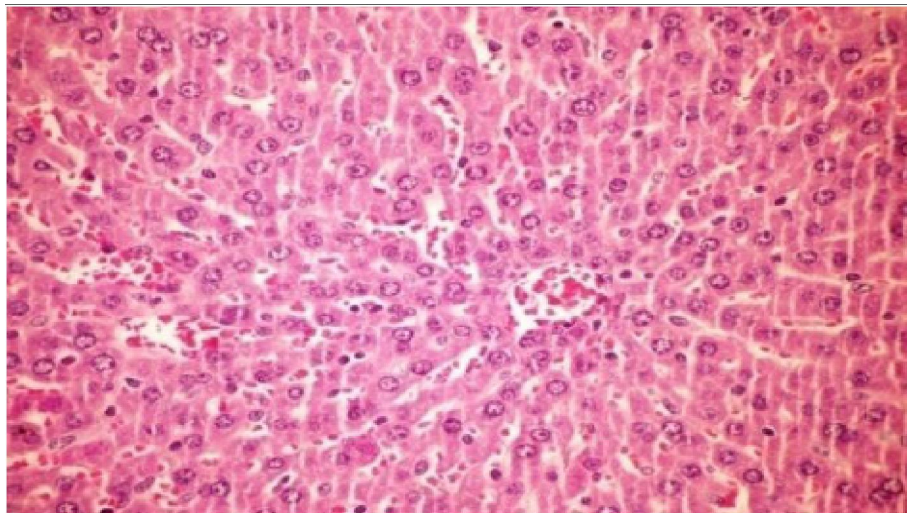


Figure 2.b : Liver of diabetic rat showing kupffer cells activation, dilation and congestion of central vein and hepatic sinusoids (H& E x 400)

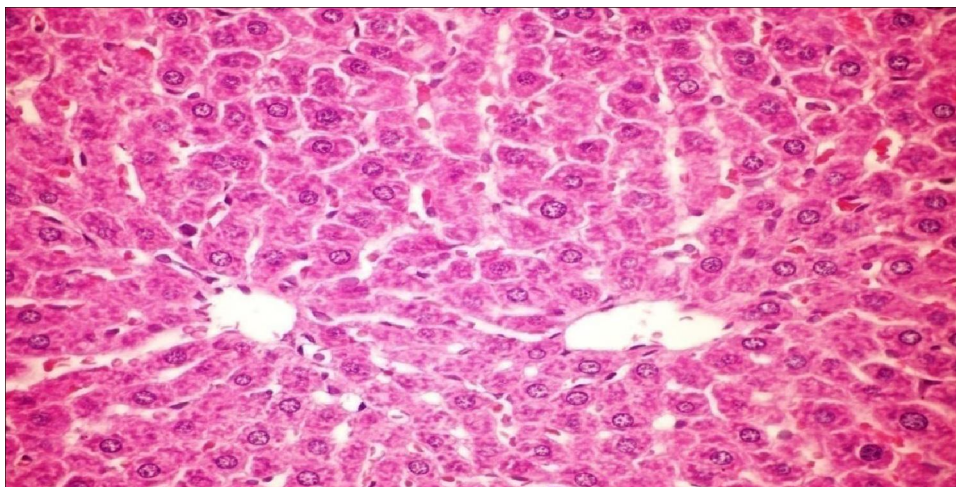


Figure 2.c : Liver section of diabetic rats treated with *HCE* (orally 400 mg/kg body weight of rats daily for 30 consecutive days) showing no histological changes (H& E x 400).

Figure 2 : Histological changes in liver of diabetic rats (H&E)

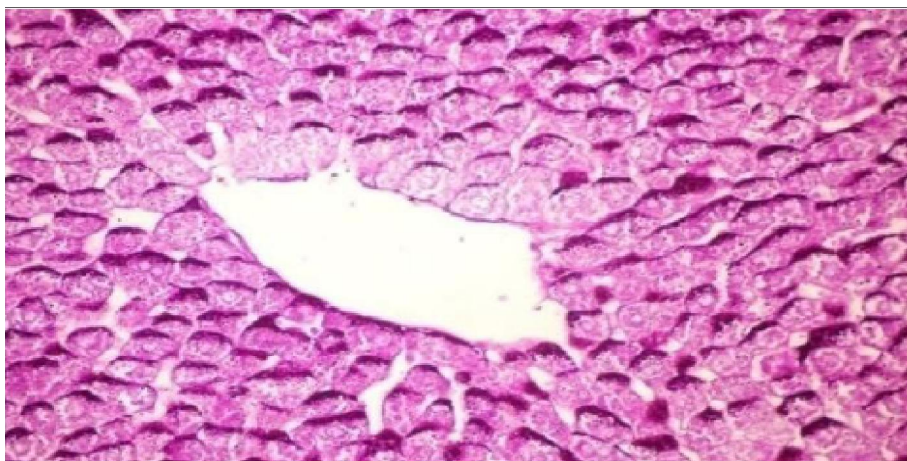Regular Paper

Figure 3.a : Liver of normal control rat showing accumulation of reddish stained glycogen particles at one pole of hepatocytes (PAs stain x 400)

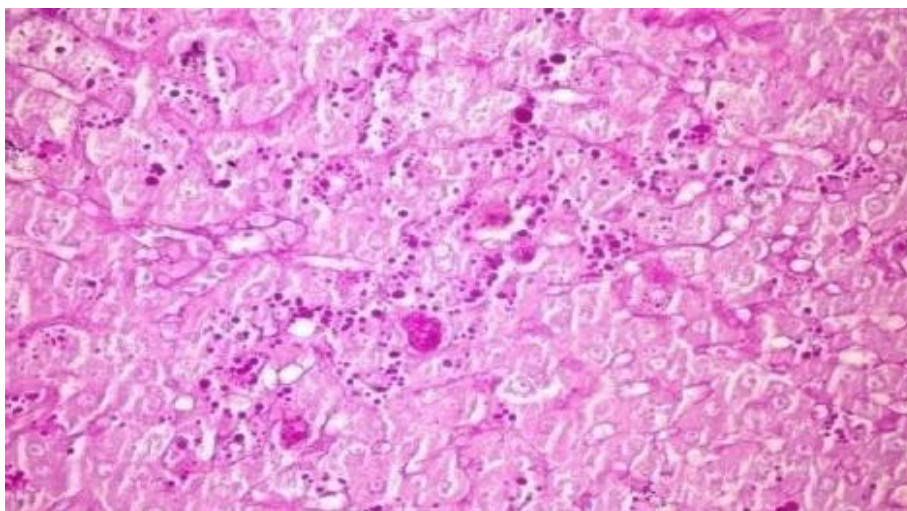


Figure 3.b : Liver of alloxan induced diabetic rat showing variable sized positive Pas glycogen particles distributed throughout the hepatocytic cytoplasm (PAs stain x 400)

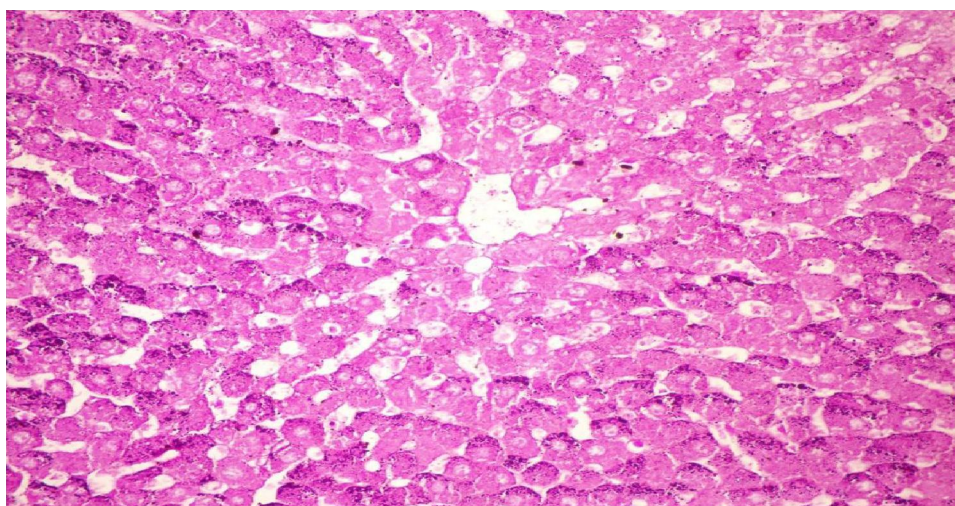


Figure 3.c : Liver of diabetic rats treated with *HCE* (orally 400 mg/kg body weight of rats daily for 30 consecutive days) showing moderate PAS particles distributed throughout the hepatocytic cytoplasm (PAs stain x 400)

Figure 3 : Histological changes in liver of diabetic rats (PAS)

increased mitochondrial membrane potential. Apparently, alloxan causes severe oxidative and cytotoxic stress to islets that is likely to compromise their insulin releasing capacity^[23].

Overproduction of ROS or exhaustion of antioxidants may cause oxidative stress which is a major factor of defective insulin secretion and increases apoptosis of pancreas^[24]. Moreover, ROS produced by β -cell in response to metabolic stress affect mitochondrial structure and function and lead to β -cell failure. Specifically, ROS oxidize mitochondrial membrane phospholipids such as cardiolipin, which impairs membrane integrity and leads to cytochrome c release and apoptosis. In addition, ROS activate UCP2 via peroxidation of the mitochondrial membrane phospholipids, which results in proton leak leading to reduced ATP synthesis and content in β -cells^[25].

However, continuous treatment of diabetic animals with HCE for 30 days caused a significant reduction in FBG level. This antihyperglycemic action may be due to explained that sulphated polysaccharides from marine algae that are known to be important free-radical scavengers and antioxidants for the prevention of pancreatic oxidative damage, which is an important contributor in DM^[26a].

The observed depletion of liver glycogen stores in diabetic rats is consistent with an earlier study^[27] indicating that it could be due to the loss of glycogen-synthase activating system and/or increased activity of glycogen phosphorylase^[28] since alloxan causes selective destruction of β -cells of the islets of langerhans resulting in a marked decrease of insulin levels, it is rational to believe that the activity of hepatic glycogen phosphorylase and hepatic glucose-6- phosphatase of diabetic animals will increased, as synthesis of glycogen depends on insulin for the influx of glucose. However, previous studies show that the reduced activity of glycogen phosphorylase and hepatic glucose-6- phosphatase hepatic by insulin treatment^[29].

Administration of HCE for 30 days also showed a trend towards a significant increase in glycogen content when compared to diabetic rats, thus confirming its insulin potentiating effect to a certain extent.

The antihyperglycemic efficacy of HCE can be correlated with the findings of^[30]. Similarly, alloxan caused body weight loss was also regained to its above-initial

values by HCE treatment, which reflects an improved health of HCE treated animals.

The histological observation of the pancreatic tissues further substantiates the claim that HCE has a protective nature on pancreatic tissue.

The characteristic features of diabetic dyslipidemia are a high plasma triglyceride concentration, low HDL-cholesterol concentration and increased concentration of small dense LDL-cholesterol particles. Faulty glucose utilization causes hyperglycemia and mobilization of fatty acids from adipose tissue for energy purpose. The lipid changes associated with diabetes mellitus are attributed to increased flux of free fatty acids into the liver secondary to insulin deficiency/ resistance. This results in excess fatty acid accumulation in the liver, which is converted to triglycerides. The impaired ability of insulin to inhibit free fatty-acid release leads to elevated hepatic VLDL-cholesterol production. The increased VLDL-cholesterol and triglyceride levels decrease the level of HDL-cholesterol and increase the concentration of small dense LDL-cholesterol particles by activation of lipoprotein lipase and lecithin acyl-cholesterol transferase

In our study, elevated levels of serum TC, TG and LDL cholesterol and decreased HDL cholesterol concentration in alloxan-induced diabetic rats^[31a]. On other hand, Induction of diabetes by alloxan resulted in loss of body weight in the diabetic control rats in accordance with^[32] that may due to catabolic effect on protein metabolism by retarding protein synthesis and stimulating protein degradation.

However, treatment with HCE normalized all the lipid profile parameters. This antihyperlipidemic attribute of bark extract may also be attributed to sulphated polysaccharides, major constituent of extract as sulphated polysaccharides enhance the negative charges of cell surface so as to effect the aggradation of cholesterol in blood, thus decreasing the cholesterol in serum^[33].

Earlier it has been explored that oxidative stress forms the foundation for the induction of multiple cellular pathways that can ultimately lead to both the onset and subsequent complications of DM. Diabetics and experimental animal models exhibit high oxidative stress due to persistent and chronic hyperglycemia, which thereby depletes the activity of antioxidative defense system and thus promotes de novo free radicals

Regular Paper

generation^[4b].

GSH oxidation is a major contributor to cell apoptosis mediated by oxidants. Accumulated evidence from our laboratory has consistently shown that an early spike in GSSG formation, typically within minutes of oxidant exposure, preceded oxidant-induced activation of mitochondrial apoptotic signaling and cell apoptosis hours later^[34].

In our study, the level of hepatic and pancreatic GSH was reduced in diabetic rats, which is consistent with an earlier report^[35]

The decrease in tissue's GSH content could be the result of decreased synthesis or increased degradation of GSH by oxidative stress that prevails during diabetes^[36]. Furthermore, lipid peroxidation is one of the characteristic features of chronic diabetes^[31b]. In the present study, along with decreased level of reduced GSH, a marked increase in the concentration of TBARS was also observed in liver and pancreas of diabetic mice; however, treatment of these animals with HCE decreased the elevated level of TBARS. Simultaneously, reduced GSH content was also increased significantly which indicates that the HCE can either increase the biosynthesis of GSH and/or reduce the oxidative stress that ultimately reduces the degradation of GSH. Similar results were also witnessed in an earlier study^[37].

Catalase is a common enzyme found in nearly all living organisms. Its functions include catalyzing the decomposition of hydrogen peroxide to water and oxygen. One of the most commonly used ROS for neuronal oxidative stress preconditioning is H₂O₂. It is formed by the dismutation of superoxide (O₂⁻) spontaneously or enzymatically in a reaction that is catalyzed by superoxide dismutase (SOD). H₂O₂ is less reactive compared to other ROS, easily crosses membranes, and diffuses from its original site of production.

Many more studies documented a pivotal role for H₂O₂ in the development of vascular dysfunction in pathological conditions, such as atherosclerosis, hypertension, and diabetes mellitus. It has also been speculated that, in the vessel wall, H₂O₂-mediated mechanisms may compensate for the loss of NO-mediated dilation during the development of various diseases^[38].

To prevent damage, it must be quickly converted into other, less dangerous substances. To this end, catalase is frequently used by cells to rapidly catalyze the

decomposition of hydrogen peroxide into less reactive gaseous oxygen and water molecules. Superoxide dismutases are a class of enzymes that catalyze the dismutation of superoxide into oxygen and hydrogen peroxide. As such, they are an important antioxidant defense in nearly all cells exposed to oxygen.

However, HCE therapy increased the activity of CAT and GSH-Px in hepatic and pancreatic tissues of treated diabetic animals. These findings can be complemented with the study of^[26b]. Reductone-associated sulphonic groups of polysaccharides can act as electron donors and can react with free radicals to convert these polysaccharides to more stable products and thereby terminate radical chain reactions^[39].

The increased activity of CAT, SOD and GSH-Px suggest a compensatory response to oxidative stress as it reduces the endogenous H₂O₂ produced thus diminishing the toxic effects due to this radical or other free radicals derived from secondary reactions^[40] and^[41]. Moreover, the observed antioxidative effect of HCE may due to synergistic action of various compounds present in the extract in contrast to the purified compound of HCE.

The histological observation of the hepatic tissues further substantiates the claim that HCE has a protective nature on pancreatic tissue.

Results of this study do not allow definite conclusion to be drawn on the mechanism of action of HCE in the experimental animal paradigms used. However, a number of investigators have shown that a host of various plant secondary metabolites possess hypoglycemic, hypotensive, anti-inflammatory and other pharmacological properties^[7b]. As mentioned earlier, HCE is also known to contain various secondary metabolites. Therefore, it is not unreasonable to speculate that some of these chemical compounds are presumably responsible for imparting the antihyperglycemic, antihyperlipidemic and antioxidative properties to HCE

From the results obtained, it can be concluded that HCE possess significant antihyperglycemic, antihyperlipidemic and antioxidative properties. Hence, apart from controlling hyperglycemia it would also be beneficial in the alleviation of associated diabetic complications including the prevention of the development of atherosclerosis and other coronary artery diseases. However, further studies are needed to investigate and

elucidate the possible mechanism of action of the active ingredients, establish complete safety profiles and evaluate the potential value of HCE for the management of diabetes and hyperlipidemia in the clinic.

Moreover, additional parameters such as assay of fructosamine, HbA1c, C-peptide etc should also be studied. This may prove helpful for developing new drugs from this plant for managing diabetes and associated complications.

ACKNOWLEDGEMENT

Authors gratefully acknowledge Vice Chancellor, El Minia, for the financial support through the Department of Agriculture chemistry

REFERENCES

- [1] M.K.Park, U.Jung, C.Roh; Fucoïdan from marine brown algae inhibits lipid accumulation, *Drugs*, **9(8)**, 1359-67 (2011).
- [2] T.Matsui, T.Tanaka, S.Tamura A.Toshima, Y.Miyata, K.Tanaka; Alphasglucosidase inhibitory profile of catechins and thioavins, *Journal of Agricultural and Food Chemistry*, **55**, 99-105 (2007).
- [3] K.Maiese, Z.Z.Chong, Y.C.Shang; Mechanistic insights into diabetes mellitus and oxidative stress, *Curr.Med.Chem.*, **14(16)**, 1729-38 (2007).
- [4] K.M.Mellor, R.H.Ritchie, L.M.Delbridge; Reactive oxygen species and insulin-resistant cardiomyopathy, *Clin.Exp.Pharmacol.Physiol.*, **37(2)**, 222-8 (2010).
- [5] F.A.Matough, S.B.Budin, Z.A.Hamid, N.Alwahaibi, J.Mohamed; The role of oxidative stress and antioxidants in diabetic complications, *Sultan Qaboos Univ.Med.J.*, **12(1)**, 5-18 (2012).
- [6] K.A.Amin, M.A.Nagy; Effect of carnitine and herbal mixture extract on obesity induced by high fat diet in rats, *Diabetol Metab Syndr.*, **16**, **1(1)**, 17 (2009).
- [7] H.Wang, L.C.M.Chiu, V.E.C.Ooi, P.O.Ang Jr; A potent antitumor polysaccharide from the edible brown seaweed *Hydroclathrus clathratus*, *Bot.*, **53**, 265-274 (2010).
- [8] R.G.Jayasooriya, Y.H.Choi, S.K.Moon, W.J.Kim, G.Y.Kim; Methanol extract of *Hydroclathrus clathratus* suppresses matrix metalloproteinase-9 in T24 bladder carcinoma cells by suppressing the NF- κ B and MAPK pathways, *Oncol Rep*, **27(2)**, 541-6 (2012).
- [9] A.H.Viswanathaswamy, B.C.Koti, A.Gore, A.H.Thippeswamy, R.V.Kulkarni; Antihyperglycemic and antihyperlipidemic activity of *Plectranthus amboinicus* on normal and alloxan-induced diabetic rats. *Indian J.Pharm.Sci.*, **73(2)**, 139-45 (2011).
- [10] P.Trinder; Plasma glucose was measured by standard methods, *Annals of Clinical Biochemistry*, **6**, 24-27 (1969).
- [11] I.Marschner, P.Bottermann, F.Erhardt, R.Linke, G.Löffler, V.Maier, P.Schwandt, W.Vogt, P.C.Scriba; Group experiments on the radioimmunological insulin determination, *Horm Metab Res.* **1**; **6(4)**, 293-6 (1974).
- [12] P.Kakkar, B.Das, P.N.Viswanathan; A modified spectrophotometric assay of superoxide dismutase, *Ind J.Biochem.Biophys.*, **21**, 130-32 (1984).
- [13] O.H.Lowry, N.J.Rosebrough, A.L.Farr, R.J.Randall; Protein measurement with the folin phenol reagent, *J.Biol.Chem*, **193**, 265-75 (1951).
- [14] A.K.Sinha; Colorimetric assay of catalase, *Anal Biochem*, **47**, 389-94 (1972).
- [15] J.T.Rotruck, A.L.Pope, H.F.Ganther, A.B.Swanson; Selenium: Biochemical role as a component of glutathione peroxidase, *Science*, **179**, 588-90 (1973).
- [16] H.Ohkawa, N.Ohishi, K.Yagi; Assay for lipid peroxides in animal tissues by thiobarbituric acid reaction, *Anal.Biochem.*, **95**, 351-58 (1979).
- [17] N.Begum, G.P.K.Sam, K.R.Shanmugasundaram; Serum enzymes I human and experimental diabetes mellitus, *Indian J.Med.Res.*, **68**, 774-784 (1978).
- [18] W.Stalmans, H.G.Hers; The stimulation of liver glycogen phosphorylase b by AMP, fluoride and sulfate. A technical note of the specific determination of the α and β forms of liver glycogen phosphorylase, *Eur.J.Biochem*, **54**, 341-350 (1975).
- [19] M.Y.Donath, P.A.Halban; Decreased beta-cell mass in diabetes: significance, mechanisms and therapeutic implications, *Diabetologia*, **47**, 581-589 (2004).
- [20] J.S.Johansen, A.K.Harris, D.J.Rychly, A.Ergul; Oxidative stress and the use of antioxidants in diabetes: Linking basic science to clinical practice, *Cardiovasc Diabetol*, **4**, 1-11 (2005).
- [21] V.P.Lebedev, S.V.Bilichenko, N.E.Ordyan, S.G.Pivina, S.P.Nechiporenko, A.A.Puzyrev, E.A.Mikheeva, K.K.Kubacheva; Transcranial electrostimulation activates reparative regeneration and the insulin-producing function of pancreatic B-cells in alloxan diabetes in rats, *Neurosci Behav*

Regular Paper

- Physiol, **37**(4), 341-7 (2007).
- [22] S.I.Rabbani, K.Devi, S.Khanam; Role of Pioglitazone with Metformin or Glimperide on Oxidative Stress-induced Nuclear Damage and Reproductive Toxicity in Diabetic Rats, *Malays J.Med.Sci.*, **17**(1), 3-11 (2010).
- [23] E.Lee, G.R.Ryu, S.H.Ko, Y.B.Ahn, K.H.Yoon, H.Ha, K.H.Song; Antioxidant treatment may protect pancreatic beta cells through the attenuation of islet fibrosis in an animal model of type 2 diabetes, *Biochem.Biophys.Res.Commun.*, **22**, 414(2), 397-402 (2011).
- [24] S.C.Du, Q.M.Ge, N.Lin, Y.Dong, Q.Su; Ros-mediated lipopolysaccharide-induced apoptosis in ins-1 cells by modulation of bcl-2 and bax, *Cell Mol Biol (Noisy-le-grand)*, **23**, 58 (2012).
- [25] Z.A.Ma; The Role of Peroxidation of Mitochondrial Membrane Phospholipids in Pancreatic β -Cell Failure, *Curr.Diabetes Rev.*, **1**, 8(1), 69-75 (2012).
- [26] Z.X.Huang, X.T.Mei, D.H.Xu, S.B.Xu, J.Y.Lv; Protective effects of polysacchride of *Spirulina platensis* and *Sargassum thunbeergii* on vascular of alloxan induced diabetic rats, *Zhongguo Zhong Yao Za Zhi*, **30**(3), 211-5 (2005).
- [27] K.Hamden, S.Carreau, K.Jamoussi, S.Miladi, S.Lajmi, D.Aloulou, F.Ayadi, VElfeki; 1Alpha, 25 dihydroxyvitamin D3: therapeutic and preventive affects against oxidative stress, hepatic, pancreatic and renal injury in alloxan-induced diabetes in rats, *J.Nutr.Sci. Vitaminol (Tokyo)*, **55**(3), 215-22 (2009).
- [28] A.Abdel-Moneim, M.El-Feki, E.Salh; Effect of *Nigella sativa*, fish oil and glicazide on alloxan diabetic rats. 1- Biochemical and Histopathological studies; *J.Egyp.Ger.Soc.Zoo*, **23**, 237-65 (1997).
- [29] N.S.El-Shenawy, I.M.Abdel-Nabi; Hypoglycemic effect of *Cleome droserifolia* ethanolic leaf extract in experimental diabetes, and on non-enzymatic antioxidant, glycogen, thyroid hormone and insuli levels, *Diabetologia Croatica*, **35**, 15-22 (2006).
- [30] H.Liu, L.Gu; Phlorotannins from brown algae (*Fucus vesiculosus*) inhibited the formation of advanced glycation endproducts by scavenging reactive carbonyls, *J.Agric.Food Chem.*, **8**, 60(5), 1326-34 (2012).
- [31] U.C.Yadav, K.Moorthy, N.Z.Baquer; Combined treatment of sodium orthovanadate and *Momordica charantia* fruit extract prevents alterations in lipid profile and lipogenic enzymes in alloxan diabetic rats, *Mol Cell Biochem.*, **268**(1-2), 111-20 (2005).
- [32] V.Levine; Insulin: the effects and mode of action of the hormone. *Vitamins and Hormones*, **39**, 145-173 (1982).
- [33] S.K.Kim, Y.X.Li; Medicinal benefits of sulfated polysaccharides from sea vegetables, *Adv.Food Nutr.Res.*, **64**, 391-402 (2011).
- [34] E.K.Pias, O.Y.Ekshyyan, C.A.Rhoads, J.Fuseler, L.Harrison, T.Y.Aw; Differential effects of superoxide dismutase isoform expression on hydroperoxide-induced apoptosis in PC-12 cells, *J.Biol.Chem.*, **278**, 13294-13301 (2003).
- [35] V.B.Brito, J.B.da Rocha, G.O.Puntel, S.C.da Luz, N.B.Barbosa, N.R.de Carvalho, V.Folmer; Inhibition of α -aminolevulinatase dehydratase is not closely related to the development of hyperglycemia in alloxan-induced diabetic mice, *Exp.Toxicol. Pathol.*, **63**(5), 443-51 (2011).
- [36] C.Soto, J.Pérez, V.García, E.Uría, M.Vadillo, L.Raya; Effect of silymarin on kidneys of rats suffering from alloxan-induced diabetes mellitus, *Phytomedicine.*, **1**, 17(14), 1090-4 (2010).
- [37] S.Hayashi, A.Itoh, K.Isoda, M.Kondoh, M.Kawase, K.Yagi; Fucoidan partly prevents CCl4-induced liver fibrosis, *Eur.J.Pharmacol*, **580**, 380-384 (2008).
- [38] T.Kobayashi, K.Kamata; Modulation by hydrogen peroxide of noradrenaline-induced contraction in aorta from streptozotocin-induced diabetic rat, *Eur J Pharmacol*, **441**, 83-89 (2002).
- [39] H.Hlawaty, N.Suffee, A.Sutton, O.Oudar, O.Haddad, V.Ollivier, C.Laguillier-Morizot, L.Gattegno, D.Letourneur, N.Charnaux; Low molecular weight fucoidan prevents intimal hyperplasia in rat injured thoracic aorta through the modulation of matrix metalloproteinase-2 expression, *Biochem.Pharmacol*, **81**, 233-243 (2011).
- [40] Y.Aisa, Y.Miyakawa, T.Nakazato, H.Shibata, K.Saito, Y.Ikeda; Fucoidan induces apoptosis of human HS-Sultan cells accompanied by activation of caspase-3 and down-regulation of ERK pathways, *American Journal of Hematology*, **78**, 7-14 (2004).
- [41] J.F.Hu, M.Y.Geng, J.T.Zhang, H.D.Jiang; An in vitro study of the structure-activity relations of sulfated polysaccharides from fbrown algae to its antioxidant effect, *J.Asian.Nat.Prod.Reports*, **3**, 353-358 (2001).